University Hospitals Birmingham NHS
NHS Foundation Trust

CONTROLLED DOCUMENT

Departmental Protocols Including Referral Criteria for Paediatric Plain Image Radiography for Primary and Hospital Referrals.

Category:	Clinical Guidelines
Classification:	Clinical
Purpose	Referral criteria for plain x-ray imaging as required under IR(ME)R 2017 for paediatrics.
Controlled Document Number:	CG1303
Version Number:	2.0
Controlled Document Sponsor:	Dr Fady Khattar. Consultant Radiologist/Director of Radiology and Diagnostics.
Controlled Document Lead:	Priti Khurana, Head of Imaging
Approved By:	Clinical Director CDG 11 Clinical Guidelines Group
Approved On:	November 2025
Review Date:	November 2028
Distribution: • **Essential Reading for:** • **Information for:**	 All Imaging staff. All Hospital referrers. GP Practices. All Staff.
Key Changes Summary (For Updated Documents)	Review of paediatric radiographic projections to reflect nationally recognised best practice.

Contents.

Paragraph		Page
1	Procedure Statement/ Purpose	3
2	Scope	3
3	Framework/ Process	5
4	Implementation and Monitoring	24
5	References	24
6	Bibliography	24
Appendices (if required)		
Appendix 1	Referral Criteria for Chest Imaging	26
Appendix 2	Referral Criteria for Abdominal Imaging	28
Appendix 3	Known or suspected button battery ingestion	29
Appendix 4	Ingestion of super strong magnets in children	30
Appendix 5	Paediatric pathway for imaging of the Cervical Spine	32
Appendix 6	Criteria for modified Stenvers projection	33

Version Control

Version No	Title	Issue Date
1.0	**Departmental Protocols Including Referral Criteria for Paediatric Plain Image Radiography for Primary and Hospital Referrals.**	11/2021

1. **Procedure Statement.**

The purpose of this document is to assist the Ionising Radiation (Medical Exposure) Regulations 2017 IR(ME)R qualified referrer in making a request for Digital Radiography (DR) imaging and to give support regarding referral pathways. Referrers may be within the hospital or external to the hospital such as GP practices but not exclusive to these settings. The document also supports radiographers in the vetting of requests prior to imaging to ensure compliance with IR(ME)R guidelines. Radiographers will also access this document to ensure the correct projections are being undertaken for each request.

2. **Scope**

This procedure/SOP applies to all DR imaging areas within the Trust QE/BHH/GH/SoL and to all individuals employed by the Trust who engage in the requesting, vetting and undertaking of DR, including, students, locum and agency staff and staff employed on honorary contracts.

The IR(ME)R 2017 have a significant impact on the requesting, reporting and management of referrals to Imaging. Under the legislation the referrer must supply sufficient medical information to enable the practitioner to justify the exposure. It is intended that the following protocols will assist the referrer and operator to ensure that the patient receives an exposure to radiation only when the result will affect the management of that patient.

A. The referrer must:

- Ensure the patient they are referring is the correct patient.
  This means double checking that the clinical details and examination required are correct for the name

- Provide sufficient information so that the patient can be uniquely identified i.e. name, date of birth, address and hospital number

- Supply sufficient medical data and a clear clinical question to enable an x-ray or scan to be justified

- Supply their own details, including a reliable contact number and a signature

  GP referral requests via the practice nhs.net account must have the GP's physical signature.

  If there is no physical signature the GP must clearly state their name on the request. This request must come from the GP's own nhs.net email address. The referrer name on the nhs.net email address must be the same as referrer on the request.

  The requests will be scanned into CRIS with a note to confirm that the request has come from the referrers email address, the email address of the referrer will also be added at this point.

B. Should a referral need to be cancelled, the department must be contacted directly and a member of staff spoken to immediately. Electronic requests cannot be cancelled using the electronic referral system.
C. Referrers must ensure that duplicate requests are not entered into the system.
D. Any urgent requests out of hours require the referrer to telephone to discuss with staff as well as providing the referral (paper or electronic).

The sharing of Usernames/Passwords is not acceptable and will not be condoned by UHB NHS Trust or any of its employees. This includes logging in on behalf of another staff member. GPs/staff members who are found to fail to abide by this condition will have their access revoked and this will be raised as a formal breach.

A period of account inactivity of 3 months or more will result in access being revoked.

The Trust is authorised to undertake spot checks on the third party at any time to check national compliance and/or completion of Local Confidentiality Agreement and/or IG training compliance.

All staff, where access is being requested, must sign a Local Confidentiality Agreement which must be held by the GP practice and available to view at any time.

IT IS THE RESPONSIBILITY OF THE GP PRACTICE TO ADVISE US WHEN STAFF LEAVE AS SOON AS POSSIBLE SO THAT WE CAN REMOVE THEIR ACCESS.

If the imaging request is incomplete or illegible, legally the examination cannot be performed.

For all x-ray examination the operator (radiographer) must ensure:

- An Imaging Department request form has been completed
- Correct identification of the patient (Procedures for Medical Imaging, procedure 1)
- Last menstrual period (LMP) check where appropriate (Procedures for Medical Imaging, procedure 4)
- Where appropriate, the patient is changed into a radiolucent gown with all radiopaque objects removed from the area of interest
- A full explanation of the procedure is given to the patient
- Any previous radiographs are available prior to the examination
- The correct radiographic views are undertaken – refer to departmental protocols and referral criteria
- The appropriate exposure is selected – refer to exposure charts
- A preprocessing marker **MUST** be on all images
- The radiation dose is as low as reasonably practicable
- Dose Area Product (DAP) or exposure details are recorded on the RIS
- The operator's name and number of exposures are recorded on the RIS

If there are any concerns about a radiological request, please seek advice and guidance from a radiologist.

3. **Framework Process**

Thorax (CXR).			
Request	**Referral Criteria**	**Projection**	**Comments**
Chest Paediatric/ Neonatology.	See Appendix 1, (page 19).	Neonates – Supine. PA- in cooperative patients AP- for non-cooperative patients or children too young for a PA projection. Supine- when clinical condition dictates, they are too unwell to be seated. Neonates. **PRE PROCESSING MARKERS ON ALL IMAGES**	Depending on the age of the baby. Pre-processing markers. QE site- Other than trauma, most children will be referred to BCH. No NNU service at QE. If there is an abnormality on a frontal chest radiograph that needs to be clarified, the standard investigation for this is now CT scanning and not a lateral chest radiograph. Imaging can be performed at the direction of a radiologist and in this case the radiologist concerned should report the examination. Lateral radiographs can still be performed to evaluate cardiac pacemakers' post-insertion and occasionally in specific cases to evaluate the position of a drain or other medical device. CXR is indicated if symptoms persist despite treatment, or in severely ill children. If CXR is used to show simple pneumonia, routine follow up CXR is not required (iRefer P01) In general, children with recurrent productive cough (at least 2 bouts/year lasting 1–2 weeks) or chronic cough of at least 4 weeks have CXRs that are normal or show peribronchial thickening. In these children, repeat CXR is not indicated unless atelectasis is seen on the initial CXR. Children with suspected cystic fibrosis or immune deficiency require specialist referral.

			Gastro-oesophageal reflux, inhaled foreign body and adenoidal/tonsil hypertrophy should be considered as alternative causes of recurrent cough. (iRefer P02).
Portable Chest.	See Appendix 1 (page 20) for clinical indications. Patient must be unable to attend department due to the severity of their condition.	AP erect/ Supine. To be determined by the patients age and compliance.	Portable images offer poor visualisation of mediastinal and vascular structures, magnification of the cardiac silhouette and compromise visualisation of lung bases.
CXR Ingested Foreign body	**Button Batteries** – **DANGEROUS** and are a **SURGICAL EMERGENCY**. Perform Lateral soft tissue neck, chest and abdominal x-ray. **Magnets** – If greater than 1 magnet or metal + magnet Perform Lateral soft tissue neck, chest and abdominal x-ray. If no choking or gagging chest and abdominal x-ray (prone if possible) only. If magnet is identified a horizontal beam lateral (HBL) abdomen of the affected area should be performed. DO NOT perform a decubitus projection. Please see NPSA alert. **Sharp and pointed objects (razor blades, safety pins, needles)** Perform Lateral soft tissue neck, chest and abdominal x-ray. If patient is asymptomatic is asymptomatic and object is not seen on x-ray proceed to watchful waiting. **Blunt foreign bodies and coins** – Chest and lateral soft tissue neck if object is radiopaque or unknown. If not seen on these projections assume it has moved to the stomach. No further x-ray unless patient becomes symptomatic. Endoscopy is definitive, consider bronchoscopy.		

Request	Referral Criteria	Projection	Comments
Ribs.	Trauma.	PA/AP (CXR).	CXR should not be requested to specifically look for rib fractures. CXR is useful to exclude pneumothorax if clinically suspected. However multiple rib fractures may indicate significant injury in the appropriate context.
Thoracic inlet.	Suspected cervical rib.	PA.	Not routinely performed. Clinical team to contact radiologist.
Sternum.	Trauma - including mechanism. Sternal swelling.	Lateral.	Collimate to sternum

Sterno-clavicular joints.	Trauma/sports injury or non-traumatic swelling of a medial clavicle.	AP view/cranial angulated view of both clavicles.	Not routinely performed. Clinical team to contact radiologist. The secondary centre on the medial end appearance on 19–20 years (2 years earlier in female) and completes at age of 25th.
Swellings and bony lumps		PA/AP ErectOblique	Discuss with Radiologist first • If lump low down, please ensure collimation includes lower costal cartilages

Abdomen (AXR).			
Request	**Referral Criteria**	**Projection**	**Comments**
Abdomen/ KUB.	See Appendix 2	AP Supine to include diaphragms and symphysis pubis. Left Lateral decubitus to help exclude perforation. Supine.	AXR is not routinely indicated for suspected appendicitis or gastro-intestinal haemorrhage. Not indicated for persistent neonatal jaundice or non-bilious projectile vomiting (suspected pyloric stenosis).

Pelvis.			
Request	**Referral Criteria**	**Projection**	**Comments**
Pelvis.	**Trauma** ? avulsion? fracture, ? dislocation,	AP and HBL.	Frog lateral if? traumatic slipped epiphysis

	Limping with unknown cause	AP Pelvis and Frog Lateral Whole leg is not advised, although ED may request whole leg if pain cannot be localised. Rationale for additional imaging is required. Discuss with radiologist for further advice.	• Without gonad protection. • ? Hip Pain: suspected irritable hip; XR, which must include a frog lateral view, if SUFE or Perthes' disease is suspected or if symptoms persist. Yield is higher in children over 9 years of age. If symptoms persist, then follow-up should be as for the limping child [RCR iRefer v7.0.2 P34]. • ? Limp (no trauma); Children with a limp require a formal clinical assessment. XR is helpful in a child with fever or unable to weight-bear and to rule out slipped epiphysis in children over the age of 9 particularly if pain persists [RCR iRefer v7.0.2 P35]. US will confirm presence of an effusion but will require aspiration to discriminate sepsis from transient synovitis, particularly in children <3 years in whom sepsis is more common. [RCR iRefer P35]
	DDH Clicking Hips	AP Pelvis +/- frog lateral , ONLY on 1st presentation or if previous x-ray was over 12 months ago	US is indicated where there is suspicion of DDH based on family history, birth history and clinical examination in an infant under six months of age. XR of the pelvis should be the first line investigation over the age of 6 months or for follow-up after initial US. [RCR iRefer P37]
	Perthes	AP Pelvis and Frog Lateral	XR must be first line of investigation although MRI and NM are more sensitive than XR in detecting occult infection/ Fracture.
	SUFE	AP Pelvis and Frog Lateral	The incidence of slipped upper femoral epiphysis is higher in children over nine years of age.
	Hip pain – Suspected Irritable Hip	AP Pelvis and Frog Lateral	Frog lateral- collimate to hip joints.
	Infection	AP Pelvis and Frog Lateral	XR has low yield on initial presentation. Frog lateral -

			collimate to hip joints. US will confirm presence of an effusion but will require aspiration to discriminate sepsis from transient synovitis, particularly in children <3 years in whom sepsis is more common. [RCR iRefer P35]
	Knee Pain ? Hip pathology	AP Pelvis and Frog Lateral	Indicated as pain could be referred from hips. Frog lateral- collimate to hip joints.

Skull and Facial Bones.			
Request	**Referral Criteria**	**Projection**	**Comments**
Skull.	In a child, fall from > 60 cm onto a hard surface, tense fontanelle, SPA.	PA/AP (only if PA cannot be obtained), Lateral and Townes.	Follow Suspected Physical Abuse (SPA) protocol for imaging, page 14. Alteration in GCS- CT following discussion with a radiologist. Generally, CT performed for trauma.
	Paediatric skull imaging is indicated in? early sutural fusion.	PA/AP (only if PA cannot be obtained), Lateral and Townes.	Plain x-ray imaging is considered when there is suspicion of craniosynostosis however US and MRI can be used for this as well (iRefer P09 page 146).
	Lump/ foreign body.	Tangential View.	Collimate to include a bony landmark on the skull, to allow the referrer/reporter to orientate the position of the lump. External foreign body marker to be used as appropriate. Consider US first.
	VP or VA shunt position	Lateral of skull and neck, AP/PA chest and AP & Lateral abdomen. **NO ABDOMEN REQUIRED FOR VA**	Usually completed as part of a shunt series to include a chest and abdominal x-ray as part of the investigation. Must have overlap with chest image. These projections to be taken in this order i.e. starting at the top to ensure overlap and shunt system integrity.

	Cochlear implant	**SHUNT** MODIFIED STENVERS See Appendix 6 for examples and positioning criteria	Use of an XR shunt series must be limited to patients with hydrocephalus confirmed by low-dose CT/MRI who specifically have suspected mechanical causes of shunt failure. To include the whole of the cochlear implant. Ideally performed erect PA but can also be performed supine depending on patient compliance. collimate to include the cochlear, not the entire head.
Orbits.	See Foreign Body section (page16).		
Facial bones.	Orbital blunt trauma, mid facial trauma.	OM OM30°.	Facial bones are not recommended on very young children, especially under the age of 12. Please seek radiologist/ advanced practitioner/reporters' advice if an opinion is required.
Nasal bones. sinusitis	Not indicated.		
Sinuses.	Not indicated.	OM (open mouth) PA 15º.	Please seek advice and guidance from a radiologist.
Mandible.	Mandibular Trauma. Cyst/abscess, Suspected tumour.	PA Mandible and OPG. PA Mandible and OPG.	RT and LT Lateral oblique if OPG not possible.
	Orthodontic assessment	OPG +/- Lateral Cephalostat	For Lateral Ceph- Back Teeth must be in occlusion; ruler positioned on the nasion. Demonstrate soft tissue profile, lips together. Must be true lateral. Valsalva manoeuvre
TMJ.	TMJ Dysfunction/Dislocation.	OPG, TMJ's.	Seek advice and guidance from a radiologist. iRefer E11 page 82 – MRI or CT indicated not plain film. Usually in older children over 12.

Cervical Spine.			
Request	**Referral Criteria**	**Projection**	**Comments**
Cervical Spine.	Trauma - Neck injury with pain.	AP Lateral Open Mouth (if child is compliant)	Lateral C spine projection first. No arm pull is to be administered, do not perform a swimmers projection. Proceed to CT if C7/T1 not demonstrated, as per adult protocol. MRI should be considered if neurological symptoms are evident. Significant trauma – may go direct to CT. Appendix 3 (page 22). Selection of Children for Imaging of the Cervical Spine. Trauma; National Institute for Health and Care Excellence, 2019. 'Head injury', NICE clinical guideline 176. London: National Clinical Guideline Centre. https://www.nice.org.uk/guidance/cg176/chapter/Update-information Helpful for identifying fractures, spondylolisthesis and congenital anomalies (iRefer).
	Juvenile idiopathic arthritis/ inflammatory arthritis.	AP. Lateral.	
	Torticollis	AP. Lateral.	Muscular causes are most common; however x-rays are advised when the history and examination are atypical to exclude causes other than congenital torticollis.
	FB – Soft Tissue neck	Lateral – use of Valsalva manoeuvre	If child is compliant

Thoracic Spine.			
Request	**Referral Criteria**	**Projection**	**Comments**
Thoracic Spine.	Trauma. Fever, tachycardia Functional disability Weight loss, bruising, adenopathy or abdominal mass Duration >4 weeks Altered spine shape/mobility Worsening pain Night pain Vertebral tenderness Morning stiffness Altered gait Past history of cancer/TB Bowel/bladder dysfunction	AP, Lateral.	Indicated only in specific circumstances Helpful for identifying fractures, spondylolisthesis and congenital anomalies. Ddiscuss with radiologist regarding further CT/MRI/NM imaging.
Thoracic Spine.	Suspected scoliosis.	GP request - AP ONLY Specialist referral- AP +/- LATERAL	Whole spine for scoliosis with stitching AP only usually unless kyphosis is also a concern, then a Lateral must also be performed. Follow positioning criteria. Follow guidance on request .

Lumbar Spine.			
Request	**Referral Criteria**	**Projection**	**Comments**
Lumbar Spine Trauma.	Trauma with lumbar area pain. Trauma. Fever, tachycardia Functional disability Weight loss, bruising, adenopathy or abdominal mass Duration >4 wks Altered spine shape/mobility Worsening pain Night pain Vertebral tenderness Morning stiffness Altered gait Past history of cancer/TB Bowel/bladder dysfunction	AP, Lateral.	Must include SIJ Indicated only in specific circumstances Helpful for identifying fractures, spondylolisthesis and congenital anomalies (iRefer). Referrer to discuss with radiologist regarding further CT/MRI/NM imaging.
Lumbar Spine Non trauma.	Suspected scoliosis.	GP request - AP ONLY Specialist referral- AP +/- LATERAL	Whole spine for scoliosis with stitching AP only usually unless kyphosis is also a concern, then a Lateral must also be performed. Follow positioning criteria. Follow guidance on request
	Osteomyelitis	Not Indicated	Consider MRI, discuss with Radiologist
	Sacrum	AP Projection 15-degree angle cranially and lateral view	Discuss with radiologist. Following trauma and referral from Orthopaedic team as part of follow-up
	Coccyx		Not indicated

Upper Extremity.			
Request	**Referral Criteria**	**Projection**	**Comments**
Shoulder.	Trauma. ? Dislocation. Non traumatic pain,	AP, Axial/Wallace view/Lateral Scapula. AP, Axial/lateral scapula,	2nd View, following the AP projection should be site and patient dependant. Projection should be selected on patient discomfort. Modify technique as appropriate
Scapula.	Trauma. Congenital. Infection.	AP, Lateral. 'Y' projection	
Clavicle.	Trauma. Infection.	AP.	If AP looks normal, a lordotic projection must be undertaken as an additional view. 20° cranial angulation
Acromio-clavicular joint.	Trauma. Suspected. Subluxation.	Coned AP.	Non-Weight Bearing. Discuss with Reporter/duty radiologist for weight bearing projections Comparison with contralateral side not indicated. Secondary ossification of the acromion begins at 10. Full fusion does not occur before the age of 20. Injuries are difficult to exclude below this age. Ask referrers to consider this.
Sternoclavicular joints.		Not indicated	Discuss with a radiologist The secondary centre on the medial end appearance on 19–20 years (2 years earlier in female) and completes at age of 25th.
Humerus.	Trauma.	AP, Lateral.	Consider ultrasound as a first line investigation for soft tissue

	Infection. Unexplained pain or deformation.		abnormalities

Upper Extremity.			
Elbow.	Trauma. Suspected arthropathy Unexplained pain or deformity. Supracondylar fracture Elbow for bone age Between 11 and 13 years of skeletal age in girls and between 13 and 15 years of skeletal age in boys, the olecranon apophysis is characterised by a clear morphological development. This method is a reliable tool to assess skeletal age during puberty because significant morphological changes in the elbow happen every six months.	AP, Lateral.	Pulled elbow can be diagnosed clinically. Only indicated if suspicion of fracture. Adapt technique as appropriate. Check for # on lateral image prior to moving into AP position to avoid brachial nerve compromise. In older children during puberty, elbow XR can be used to evaluate bone age. Check with a paediatric radiologist if this is reasonable practice. (iRefer guidance). **Currently not routinely performed. Discuss with paediatric radiologist prior to imaging.**
Radius/ Ulna.	Trauma. Unexplained pain or deformity.	AP, Lateral.	
Wrist.	Trauma. Unexplained pain or deformity. ? Rickets	PA, Lateral. DP of LEFT wrist	**Referrer may ask for a left knee OR a DP left wrist.** **See further information for Rickets below** • Further joint views (AP/DP only by default) may be considered if the referrer has clearly specified a concern (e.g., deformity, injury) for a particular region.

Scaphoid.	Trauma.	PA (ulnar deviation), Lateral, AP and PA oblique, 30 degree angulation.	Scaphoid ossifies at 4-6 years. Discuss with a radiologist if child is younger than 4 years.
Hand.	Trauma. Unexplained pain or deformity.	DP, Oblique.	Lateral view for fractured/ displaced metacarpals. Soft tissue exposure for FB.
Hand and wrist for bone age.	Short stature Tall stature Precocious puberty Delayed puberty Anorexia nervosa Eating disorder Liver transplant assessment	PA hand and wrist NB- <u>The left or Non dominant hand must be imaged.</u>	The left hand and wrist must be included with the axis of the middle finger in direct axis with forearm. • The upper arm and forearm should be in the same horizontal plane • Centre at head of the 3rd metacarpal • The FFD of 76cms • The fingers slightly separated and the thumb in a comfortable position at about 30 degrees to the first finger. This must be performed on children one year and over. Discuss with a radiologist if child is under 1.
Thumb.	Trauma. Unexplained pain or deformity. Foreign body	AP, Lateral.	Include 1st carpometacarpal joint. Use FB marker
Fingers.	Trauma. Unexplained pain or deformity. Foreign body	AP/PA, Lateral.	Oblique projection for fingers which are strapped. Use FB marker
Requests for comparison projections of the other limb are not indicated. Seek Radiological advice.			

Lower Extremity.			
Request	**Referral Criteria**	**View**	**Comments**
Leg length Examination	Genu Valgum Genu Varum Leg length discrepancy	AP +/- lateral (as specified by orthopaedic consultant)	Standing where possible. Standing where possible. At least hip and ankles must be included, but ideally iliac crests to ankles Ruler must be present on image. Consider CT at discretion of Orthopaedic team. Patella must be forward facing. If this is not achievable on one projection, image the legs individually.
Femur.	Trauma. Unexplained pain or deformity. Fracture Follow up Osteomyelitis	AP, Lateral.	
Knee.	Trauma with inability to weight bear or pronounced bony tenderness. Unexplained pain or deformity. Locking. Rickets • Further joint views	AP Horizontal beam lateral. AP and turned lateral. AP LEFT knee	Knee views must not be undertaken for Osgood Schlatter disease. Although bony radiological changes are visible in Osgood–Schlatter disease, they overlap with normal appearances. Associated soft tissue swelling should be assessed clinically rather than radiographically. Traction apophysitis of the growth plate should be treated symptomatically Skyline and intercondylar views are specialist orthopaedic referral only. **Referrer may ask for a left knee OR a DP left wrist.**

	(AP/DP may be considered if the referrer has clearly specified a concern (e.g., deformity, injury) for a particular region.		Impaired mineralization of the growth plate can be confirmed by typical radiography of the wrist or knee, showing metaphyseal fraying and widening of growth plates
Tibia and Fibula.	Trauma, with inability to weight bear or pronounced bony tenderness. Unexplained pain or deformity. Fracture Follow up Osteomyelitis	AP, Lateral.	
Ankle.	Trauma with inability to weight bear or pronounced bony tenderness. Unexplained pain or deformity. Fracture Follow up Osteomyelitis	AP, Lateral.	Include the base of the 5th metatarsal on the lateral projection**.** WB projections on request from the T&O consultant.
Calcaneum.	Trauma with an inability to weight bear. Fracture Follow up Osteomyelitis	Lateral, Axial.	
Foot.	Trauma. Fracture Follow up Osteomyelitis ? Foreign body	DP, Oblique. DP and Lateral	Lateral view for dislocation or fracture of the tarsals or metatarsals. With FB marker
Toes.	Trauma. Osteomyelitis ? Foreign body	DP, oblique. DP and Lateral	With FB marker
Hallux.	Trauma.	DP, Lateral.	
Requests for comparison projections of the other limb are not indicated. Seek Radiological advice.			

Paediatric Skeletal Surveys.			
Skeletal Dysplasia. **Discuss request with a radiologist.**	• Chest • Pelvis • Skull • Left humerus • Left forearm • Left hand and wrist for bone age • Left femur • Left tibia/fibula • Thoraco-Lumbar Spine	PA/AP AP Lateral AP AP DP hand and wrist NB- The left or Non dominant hand must be imaged. AP AP AP/Lateral	To include all ribs The middle finger must be in alignment with the wrist, no deviation of the wrist. This must be performed on children one year and over. May require separate views in older patients

Suspected physical abuse (SPA) – Initial Presentation. **MUST DISCUSS WITH CONSULTANT RADIOLOGIST.**			
Skull.	Skull X-rays should be taken with the skeletal survey even if a CT scan has been or will be performed.	AP, Lateral and Townes.	CT images alone are not sufficient.
Chest.	Left and Right Oblique views of both sides of the chest and all 12 sets of ribs.	AP including the clavicles and all 12 sets of ribs.	
Abdomen.	AP of abdomen including the pelvis and both hips.	Supine.	
Spine.	If the whole of the spine is not seen in the AP projection on the chest and abdominal imaging, then additional views will be required.	Right Lateral.	This may require separate exposures of the cervical, thoracic and thoraco-lumbar regions. AP view of the cervical spine is rarely diagnostic at this age and should only be performed at the discretion of the supervising practitioner.
Limbs.	• Both Humeri • Both Radiuses and Ulnae • Both Femora • Both Tibiae & Fibulae • Both ankles (Mortice) • Both Hands & Wrists • Both Feet • Both Elbows • Both Wrists • Both Knees • Both Ankles	• AP • AP • AP • AP • AP • DP • DP • Laterals • Laterals • Laterals • Laterals	

Suspected physical abuse (SPA) – Follow up Projections. **MUST DISCUSS WITH CONSULTANT RADIOLOGIST.**			
Chest.	AP including the shoulders and all 12 sets of ribs.	AP. Left and Right Oblique views of both sides of th chest and all 12 sets of ribs.	
Limb.	• Both Humeri • Both Radiuses and Ulnae • Both Femora • Both Tibiae & Fibulae	• AP • AP • AP • AP	
Additional.			Follow-up radiographs must be performed of any abnormal or suspicious areas on the initial skeletal survey as per radiologist.

Foreign Body.			
Request	**Referral Criteria**	**Projection**	**Comments**
Skull.	Foreign Body in scalp.	Tangential view.	Soft tissue exposure. To include skin marker. Collimate to include bony landmark.
Orbits.	FB – trauma only. Pre MRI screening.	OM - Eyes up and eyes down. PA 20 eyes up.	
Upper and Lower Extremities	Penetrating injury. (Type of FB must be specified).	e.g. AP/PA and Lat. A tangential view may be helpful to localize a foreign body.	Use a marker to localize the entry wound. Remove dressings where appropriate.
Throat.	Swallowed Foreign Body.	Lateral Cervical spine	Soft tissue exposure, Valsalva manoeuvre.
Chest and/or Abdomen.	**Button Batteries** – **DANGEROUS** and are a **SURGICAL EMERGENCY**. Perform Lateral soft tissue neck, chest and abdominal x-ray. **Magnets** – If greater than 1 magnet or metal + magnet Perform Lateral soft tissue neck, chest and abdominal x-ray. If no choking or gagging chest and abdominal x-ray (prone if possible) only. If magnet is identified a horizontal beam lateral (HBL) abdomen of the affected area should be performed. DO NOT perform a decubitus projection. Please see NPSA alert (next page). **Sharp and pointed objects (razor blades, safety pins, needles)** Perform Lateral soft tissue neck, chest and abdominal x-ray. If patient is asymptomatic is asymptomatic and object is not seen on x-ray proceed to watchful waiting. **Blunt foreign bodies and coins** – Chest and lateral soft tissue neck if object is radiopaque or unknown. If not seen on these projections assume it has moved to the stomach. No further x-ray unless patient becomes symptomatic. Endoscopy is definitive, consider bronchoscopy. Ingested button battery requests must be dealt with urgently. Pathway for the ingestion or suspected ingestion of extra strong rare earth magnets –Appendix 4.		

NPSA Alert. **Ingestion or suspected ingestion of extra strong rare earth magnets.**			
Request	**Referral Criteria**	**View**	**Comments**
Abdomen +/- Chest.	**NPSA Alert:** Ingestion or suspected ingestion of extra strong rare earth magnets. Neodymium magnets (also known as NdFeB, NIB, Neo magnet or Super Strong Rare-Earth Magnets. Rare earth magnets are between five and ten times stronger than ceramic magnets and are sometimes called 'super strong' or powerful magnets.	Erect Chest X-ray and abdominal X-ray (with the patient lying down prone if possible). Image clearly marked as prone or supine. In the case of a single magnet being identified on an abdominal X-ray, a HBL supine abdominal X-ray must also be performed to confirm that only one magnet has been ingested and to check for perforation. DO NOT PERFORM A LATERAL DECIBITUS. A lateral chest x-ray must be performed if a single magnet is seen in the chest.	Follow up abdominal X-ray must be performed at 6-12 hours in those patients who are asymptomatic (only repeat CXR if magnets are seen in the chest on the first image). It is essential that the abdominal radiographs are always performed in the same position (lying down, ideally prone). Repeat imaging may be requested every 6-12 hours until it can be demonstrated that the magnet has passed through the stomach, and it is progressing through the small bowel or beyond. Continuation with imaging will usually be on confirmation of a single magnet being ingested. Urgent report is required. Notify referrer when the image had been reported. External magnetic objects nearby, clothes with metallic buttons or belts with buckle should be removed from the patient.

4. Implementation and Monitoring

a. Implementation

i. This document will be discussed at staff meetings and all staff will be notified of the document update via email and departmental newsletter. Referrers will be notified by comms.

b. Monitoring

i. This document will be updated in accordance with any updates of relevant policies and procedures within the trust.

5. References

iRefer. Royal College of Radiologists 8th Edition

Birmingham Women's and Children's NHS Foundation Trust. Plain Film Imaging Referral & Justification Criteria (2020).

Hafner D, Leifheit-Nestler M, Grund A, Schnabel D. *EDUCATIONAL REVIEW Rickets guidance: part I—diagnostic workup*. Pediatric Nephrology (2022) 37:2013–2036 https://doi.org/10.1007/s00467-021-05328-w

Makaju S, Karmacharys M, Chaudhary S. *Age Determination by Medial End of Clavicle- Radiology Study.* Journal of College of Medical Sciences-Nepal, Vol-18, No 2, Apr-Jun 2021 DOI: 10.3126/jcmsn.v17i2.36773

Ogawa K, Matsumura K, Yoshida A, Inokuchi W *Nonunion of the so-called acromion: a systematic review with consideration of the terminology* Arch Orthop Trauma Surg . 2023 Jun 14;143(9):5727–5740. doi: 10.1007/s00402-023-04912-z

- A Kyung-Sik , B Byeonguk, J Woo Young, L Jin Hyuck, O Saelin , K Baek Hyun , L Si Wook, J Hae Woon, L Jae Won , S Jinkyeong, J Kyu-Hwan, K Chang Ho, H Soon, L Hyuck. *Assessment of rapidly advancing bone age during puberty on elbow radiographs using a deep neural network model*
Paediatric Published: 11 June 2021. Vol 31, pp8947–8955.
https://doi.org/10.1007/s00330-021-08096-1

6. Bibliography

University Hospitals Birmingham Ingested or Inhaled Foreign Bodies in Paediatrics (including Button batteries and Magnets).
IngestedInhaledForeignBodiesPaediatrics.pdf

Royal College of Emergency Medicine Best Practice Guideline Ingestion of Super Strong Magnets in Children; May 2021.
RCEM_BPC_Ingestion_of_Super_Strong_Magnets_in_Children_170521.pdf

National Patient Safety Alert NatPSA/2021/002/NHSPS ‘Urgent assessment/treatment following ingestion of ‘super strong’ magnets’, issued 19th May 2021. NaPSA-Alert-Magnets-FINAL-v5.pdf

Appendix 1.

Referral Criteria for Chest Imaging.

Acute Stridor - Acute stridor is most commonly due to infection (croup or epiglottitis) or an inhaled foreign body. Chest XR and lateral neck XR may be of value in a child with a stable airway in whom an inhaled foreign body or retropharyngeal abscess is possible. Endoscopy is definitive, consider bronchoscopy.

Respiratory Distress Syndrome (RDS)

Broncho Pulmonary Dysplasia (BPD)

Pulmonary Interstitial Empyema (PIE)

Chronic Lung Disease

Meconium Aspiration Syndrome

Pneumothorax

Chest Infection

Abnormal blood gases

Pneumomediastinum

Position of catheters/lines/tubes

Pleural Effusion

Previous antenatal ultrasound abnormality suspected

Congenital Heart Disease

Line position

INHALED FOREIGN BODY

At risk:

- Children under the age of 5
- Older children with developmental delay

Most commonly organic matter- i.e. food

Clinical Presentation

- Suspect if:

Sudden onset of respiratory symptoms especially coughing or choking
New wheezing that does not respond to usual treatment
Unexplained persistent wet cough
Recurrent or persistent pneumonia

DETAILED history- parents may or may not give clear history of witnessed choking episodes.

May have diminished breath sounds or unilateral wheeze on auscultation

Clinical examination may be **UNREMARKABLE**

Management

IF LIFE THREATENING or currently choking: APLS choking algorithm

- CXR - this may be **NORMAL**
- May also see:
  - Radiopaque foreign body
  - Hyperinflation
  - Persistent lobar collapse
  - Unilateral chest signs

• If **HISTORY** or PRESENTATION suggests inhalation, **REFER** for urgent bronchoscopy even in absence of any clinical findings (ENT if above clavicles, respiratory/surgical if below)

Appendix 2.

Taken from the 'Referral Criteria for Abdomen'. (iRefer Guidance 2017. 8th Ed.)

Indicated:

- Ingested Foreign body – adhere to agreed imaging for this presentation.

Indicated in specific circumstances:

- Blunt abdominal trauma.
- Recurrent vomiting in children. May identify the level of bowel obstruction.
- GI bleeding per rectum if necrotising enterocolitis is suspected.
- Acute abdominal pain. Rarely of value. Ultrasound (US) is first line investigation (iRefer).
- Constipation- only in specific circumstances, not indicated for diagnosis or monitoring response to treatment.

Not indicated

- Intussusception in children. (iRefer)

University Hospitals Birmingham NHS
NHS Foundation Trust

Appendix 3

Known or suspected button battery ingestion

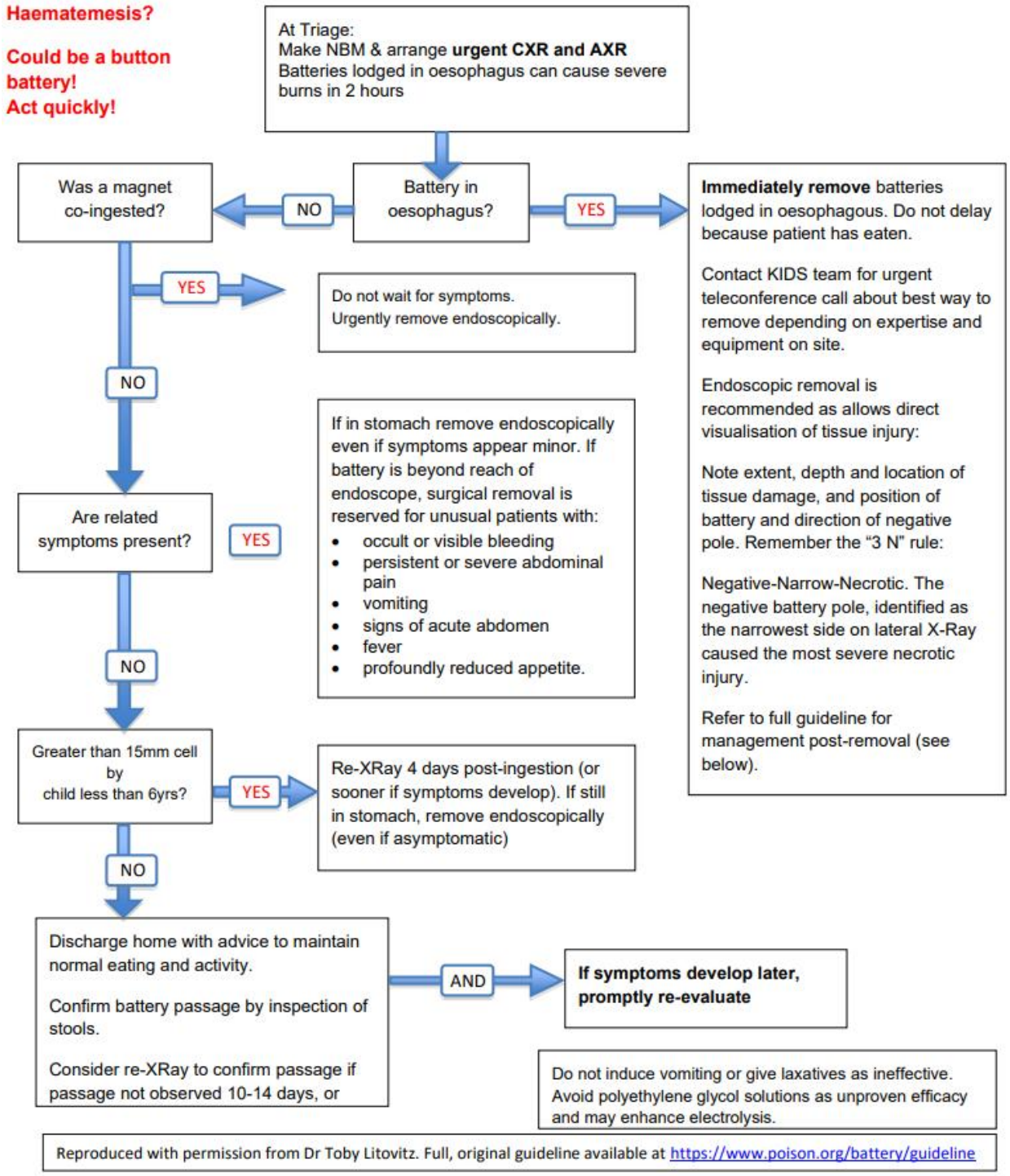

Reproduced with permission from Dr Toby Litovitz. Full, original guideline available at https://www.poison.org/battery/guideline

Appendix 4

Ingestion of super strong magnets in children

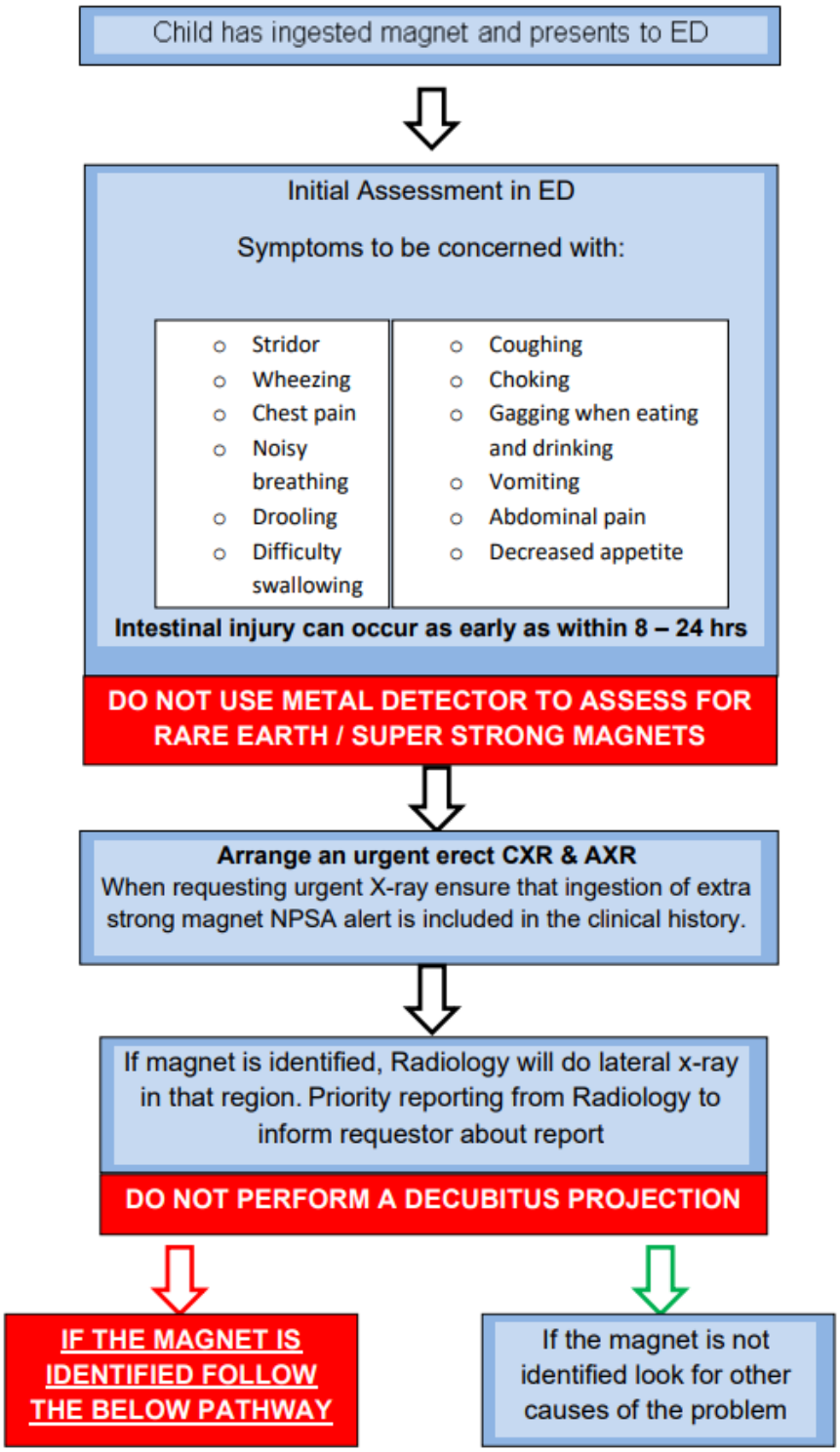

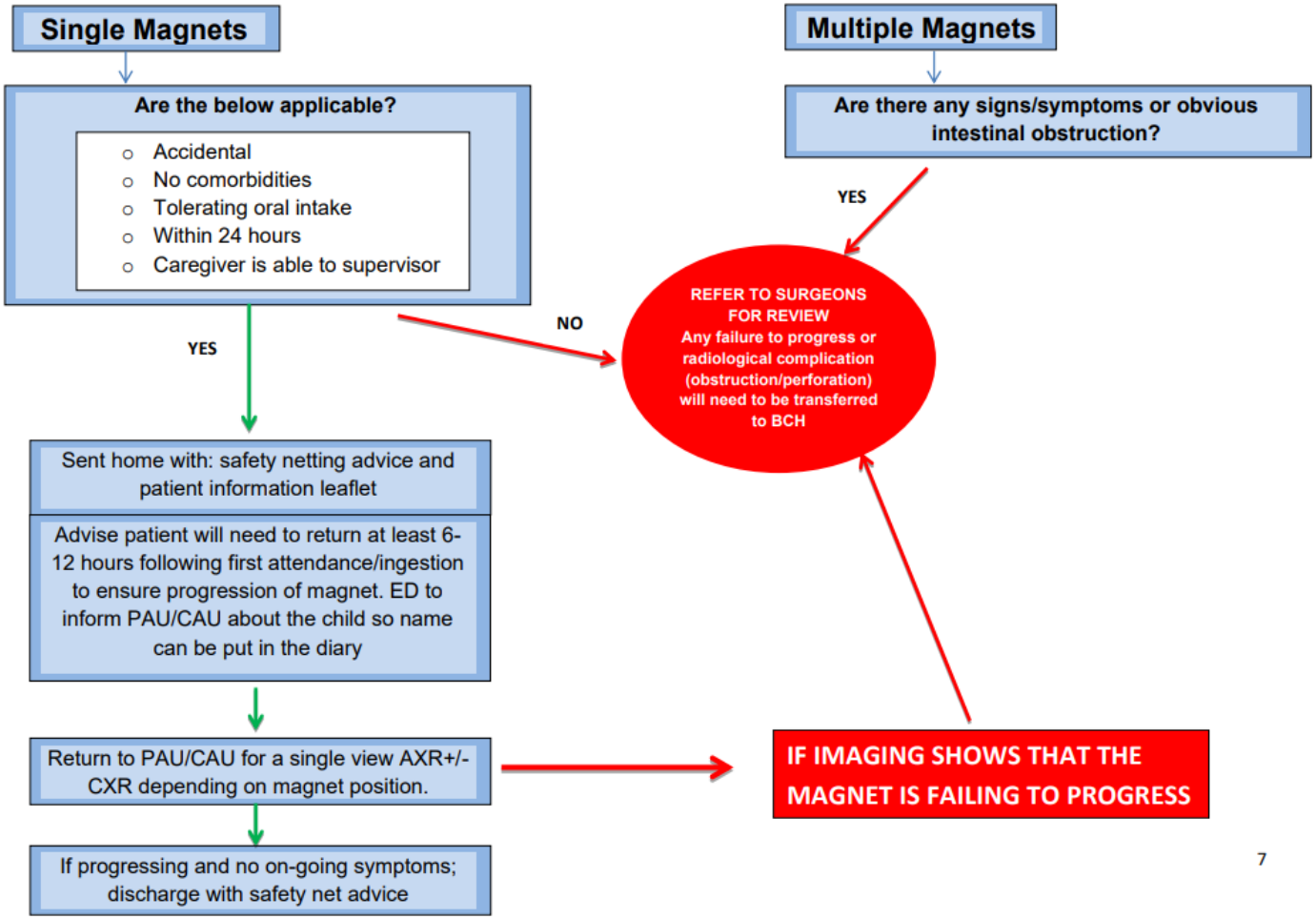
Single Magnets
Are the below applicable?
Accidental
No comorbidities
Tolerating oral intake
Within 24 hours
Caregiver is able to supervisor
YES
NO
Sent home with: safety netting advice and patient information leaflet
Advise patient will need to return at least 6-12 hours following first attendance/ingestion to ensure progression of magnet. ED to inform PAU/CAU about the child so name can be put in the diary
Return to PAU/CAU for a single view AXR+/- CXR depending on magnet position.
If progressing and no on-going symptoms; discharge with safety net advice
Multiple Magnets
Are there any signs/symptoms or obvious intestinal obstruction?
YES
REFER TO SURGEONS FOR REVIEW
Any failure to progress or radiological complication (obstruction/perforation) will need to be transferred to BCH
IF IMAGING SHOWS THAT THE MAGNET IS FAILING TO PROGRESS
7

Appendix 5

Selection of Children for Imaging of the Cervical Spine.

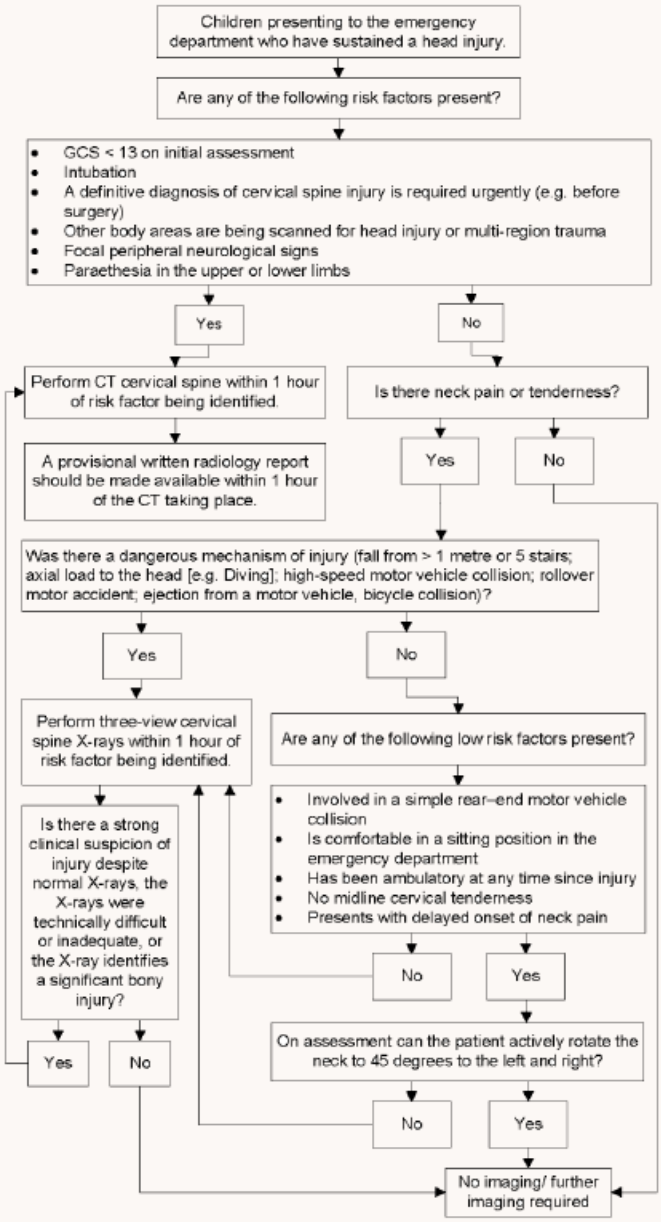

National Institute for Health and Care Excellence. *CG 176 Head Injury: Triage, assessment, investigation and early management of head injury in children, and adults*. London: NICE, 2014. Reproduced with permission.

Appendix 6

Modified stenvers for cochlea implant showing normal position of the electrode array, medial to the expected location of the cochleostomy.

Positioning.
Patient is sitting upright or standing erect facing the imaging plate. Rotate the patients head 30° so that the cheek of the side of interest is closest to the to image detector.
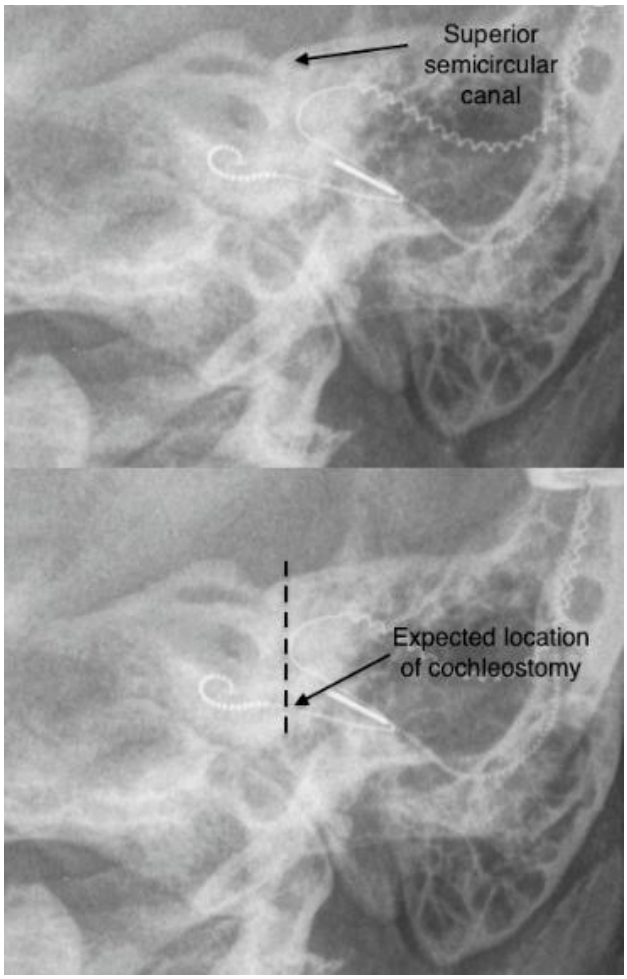
Modified Stenvers view | Radiology Case | Radiopaedia.org